

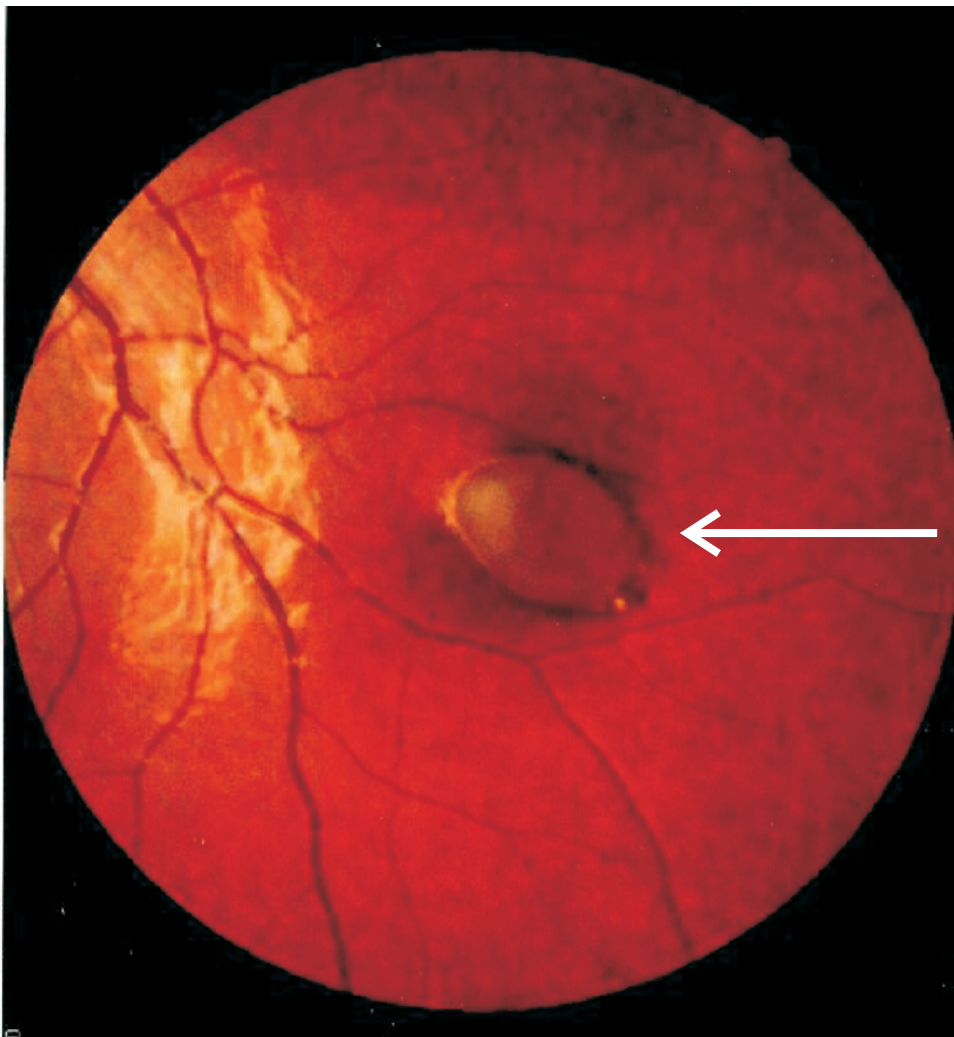
Retinal lesion in a 13 year old boy with a family history of colorectal cancer

Nusliha A, MBBS¹, Jayatunge D.N.U, MBBS¹, Dalpatadu K.U.A, MBBS, MS²,
Amarasinghe B, MBBS, MS.³

1 Research Assistant, Professorial Surgical Unit, North Colombo Teaching Hospital, Ragama.

2 Senior Surgical Registrar, Professorial Surgical Unit, North Colombo Teaching Hospital, Ragama.

3 Consultant Surgeon, Ophthalmology Unit, North Colombo Teaching Hospital, Ragama.⁷



This retinal lesion (arrow) was detected at routine examination in a 13 year old boy. His father had colorectal cancer and his sister has multiple polyps in her large bowel.

1. What is this lesion?
2. What is the large bowel condition associated with this lesion?

Find the answers on page 40