

IMAGE QUIZ

Quiz 1

L.Paranaheva

Consultant Radiologist, Asiri Surgical Hospital, Sri Lanka

A 46 year old male patient presented with acute haematemesis. An upper gastrointestinal endoscopy showed haemobilia.

- 1: What is the investigation shown in Figure 1?
- 2: What arteries are indicated by the arrows?
- 3: What is the abnormality seen in Figure 2?
- 4: What is the treatment?

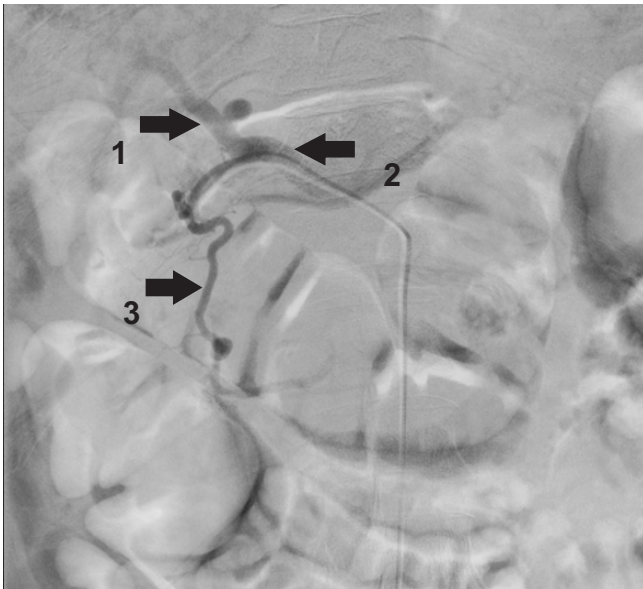


Figure 1

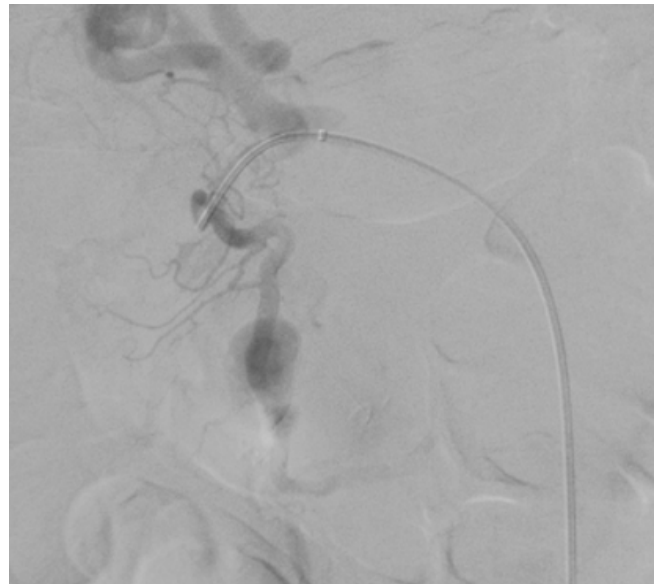


Figure 2

Quiz 2

P.Shetty, L.F.Tauro, A.Alva

Department of General Surgery

Father Muller Medical College and Hospital, Mangalore, Karnataka, India.

A 6-year-old girl was admitted complaining of difficulty articulating speech and inability to protrude her tongue. On oral cavity examination, there was a string of tissue attached to the tip of her tongue to the floor of the mouth, restricting her tongue movement [Fig 1]. The rest of her physical examination was normal. She attained milestones at appropriate age and has no family history of similar complaints.

1. What is the diagnosis?

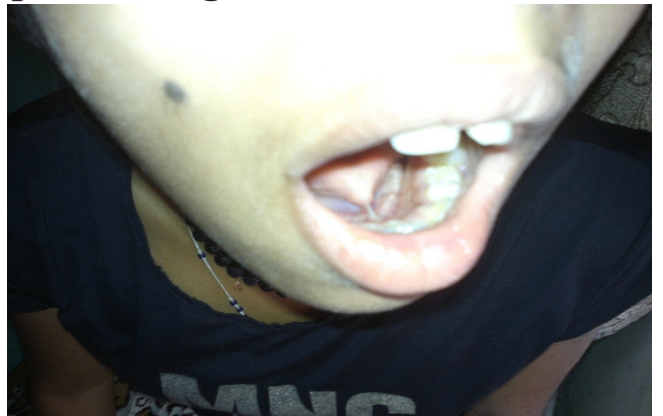

Figure 1

Answers - Page 41