

## Botulinum toxin injection to the puborectalis in the management of pelvic floor dyssynergia.

I.H.D.S Pradeep<sup>1</sup>, P.C Chandrasinghe<sup>2</sup>, S.A.S.R Siriwardana<sup>3</sup>, S.K Kumarage<sup>2</sup>

1 Professorial Surgical Unit, Colombo North Teaching Hospital, Ragama.

2 Department of Surgery, University of Kelaniya, Ragama.

3 Department of Radiology, Colombo North Teaching Hospital, Ragama.

### Introduction

Pelvic floor dyssynergia (spastic pelvic floor) is a functional disorder that causes difficulty in evacuation of the rectum [1]. This entity is an under diagnosed condition which requires dynamic pelvic MRI as the current investigation of choice. Treatment includes biofeedback therapy, injection of botulinum toxin in to puborectalis ring and surgical division of the puborectalis ring. Surgical division of puborectalis ring has irreversible effects and has a risk of causing incontinence [2]. Botulism toxin injection provides a reversible paralysis of the puborectalis allowing the chance of diagnosis and treatment in short term.

This brief report describes the technique of Botulinum toxin injection to puborectalis sling in a patient diagnosed with pelvic floor dyssynergia.

### Clinical diagnosis

A 37 year old mother of two children presented with a history of recurrent anal fissures with chronic anal pain and difficulty in evacuation of the rectum for two years duration. There was sensation of incomplete bowel emptying and tightness of the perineum. She had adopted an unusual position to defecate in order to overcome the difficulty and had to strain more than thirty minutes at a time. She had undergone lateral internal anal sphincterotomy and didn't have significant improvement. She didn't have a past history of abdominal or pelvic surgeries. She had two normal vaginal deliveries and there was no history of obstetric complications or instrumental delivery. On examination there was no rectal prolapse, perineal floor descent or

perianal lesions such as fistulae, fissures or hemorrhoids. On digital rectal examination anal tone was normal. She underwent colonoscopy which was normal. A dynamic pelvic MRI was done which revealed a prominent puborectalis with impingement at the anorectal angle (paradoxical movement) while straining indicating spastic pelvic floor. A grade I rectocele was also present (Figure 1; a & b). Considering the clinical scenario it was decided to proceed with botulinum toxin injection under ultra sound guidance to the puborectalis sling as a short term therapeutic trial.

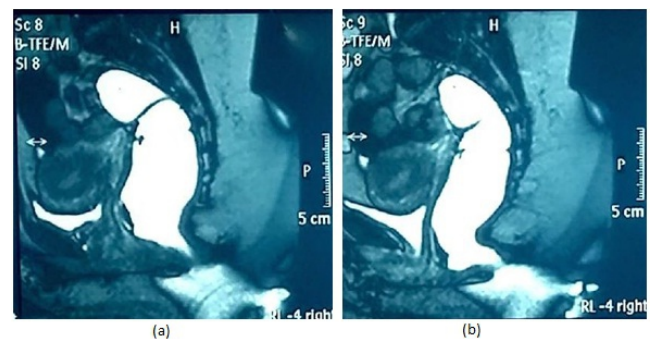


Figure 1. Dynamic pelvic MRI at rest (a) and increased anorectal angle during straining (b)

### Technique

After taking written informed consent the patient was positioned in the lithotomy position under spinal anesthesia. Perineum and upper thigh were cleaned with 10% povidone iodine and draped with perineal towels. Real time perineal ultrasound scan was performed using a high frequency (10 MHz ) linear probe to demonstrate the anatomical structures. In visualizing the structures the probe was held perpendicular to the perineum on either side of the anus and at the perineal body. The anal sphincter complex and the puborectalis ring were

Correspondence: I.H.D.S Pradeep  
E-mail: samaniddagoda@gmail.com

identified (Figure 2). The anal sphincter complex appears on ultrasonography as a hypoechoic ring shadow. The puborectalis appears as a 'V' shaped mixed echogenic shadow encircling the sphincters. With sonographic guidance a 26g needle was introduced in to the puborectalis sling and 50 units of botulinum toxin was injected in to each limb of the puborectalis sling under sonographic guidance. Although the needle cannot be visualized sonographically the movement of muscle fibres with the penetration of the needle is used as a guide. Post operatively the patient was managed with oral analgesia and syrup lactulose 30 ml nocte. She was advised to have a fibre rich diet and adequate amount of water. Using of a squatting pan for the act of defecation was recommended as the pelvic floor muscles are maximally relaxed in this position. Patient was discharged on post procedure day one and reviewed at post procedure two weeks. Patient had dramatic improvement of symptoms with biofeedback, two weeks after the procedure. On further follow up her symptoms reappeared at 1 month following the procedure. Injection of botulinum toxin was done for the second time in the same manner.

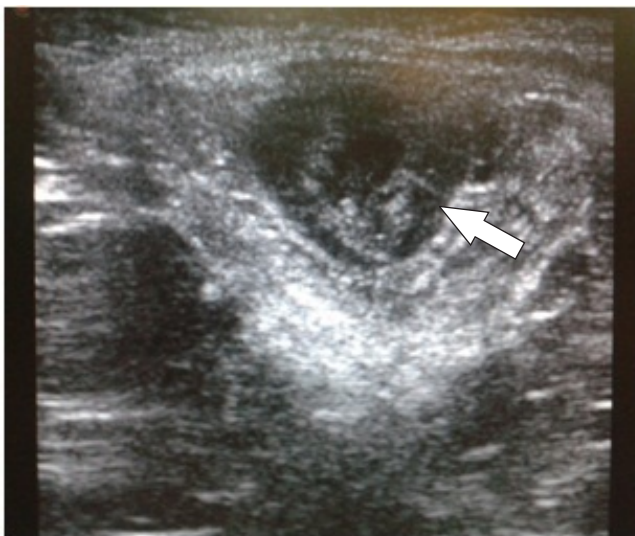

Figure 2. Ultrasonographic view of the puborectalis muscle (arrow)

### Discussion

Pelvic floor dyssynergia (anismus) is a functional disorder due to spastic pelvic floor leading to defective relaxation of pelvic floor muscles resulting in evacuation difficulty during the act of defecation. The exact etiology for this is not well recognized. Chronic straining is thought to be the main cause resulting in the

loss of muscle coordination specifically of the puborectalis part of the levator ani. These patients are often misdiagnosed and continue to have constipation and evacuation difficulty for a long period of time. In analyzing their symptoms these patients fulfill the ROME II criteria for functional constipation. Currently the dynamic pelvic MRI is the choice of imaging which shows defective relaxation of puborectalis sling and pelvic floor muscles causing an acute ano rectal angle during evacuation causing obstructed defaecation [8]. Other available investigations are defaecation proctography, balloon expulsion, anorectal manometry and electromyography of the pelvic floor muscles. Lower GI endoscopy is mandatory to exclude colonic pathology. Validated standard questionnaires (PAC- SYM, PAC-QOL) are used to assess the severity of the symptoms and response following treatment. Treatment modalities consist of Biofeedback therapy, botulinum toxin injection to the puborectalis sling and surgical division of the puborectalis muscle. Bio feedback therapy is morbidity free effective therapy for well motivated patients diagnosed of having this condition. Gadel Hak et al. reported 91.6% subjectively overall improvement of symptoms in a group of 60 patients who underwent biofeedback therapy [5]. Although it has been shown to have limited therapeutic effect in clinical practice [6] botulinum toxin injection is useful in relieving symptoms in the short term which causes transient relaxation of puborectalis sling allowing confirmation of the diagnosis. It has higher success rates compared to biofeedback training alone [7]. Muscle coordination can be regained once the spasticity is relieved with botulinum toxin. Symptoms tend to return in few months when the effect of the drug weans off. There has been no severe side effect observed following injection of botulinum toxin to treat benign anal conditions [4]. Farid M and El Monem et al compared biofeed back therapy over Botulinum toxin injection in forty eight patients with anismus [3]. Patients were assessed for initial improvement at one month and long term success rate at one year in this study. Patients who had biofeedback(BF) therapy had 50% initial improvement and 25% long term success rate and patients had Botulinum toxin had 70.8% initial improvement with 33.3% long term success rate. They concluded highlighting the limited therapeutic effect of biofeedback therapy and higher temporary success rate

of botulinum injection (BI). Partial surgical division (PSD) of the puborectalis sling bilaterally is the definitive surgical treatment indicated for anismus. This procedure is found to be an effective method with low morbidity and higher success rates compared to non pharmacological methods. Previous authors have administered botulinum toxin with the assistance of endoanal ultrasound or electromyography of the puborectalis, methods which are not freely available in the local setting [12]. We describe the technique performed with the use of perineal ultrasound scanning which is a non-invasive freely available modality. The drawback of surgical division is the risk of causing irreversible incontinence. Faried M et al conducted a study on 60 patients who were randomly allocated to receive either one of the three modalities of treatment with a follow up of up to one year [3]. The groups differed significantly with regard to functional outcome at 1 month (50% - BF, 75% - BI, 95% - PSD). The difference persisted at one year post procedure. They concluded that bilateral PSD of puborectalis has higher success rate with less morbidity in the long run. Incontinent for flatus or faeces (13%) and pelvic floor descent (26%) were the complications observed in this series with PSD. It was decided to proceed with PSD of puborectalis in our patient as the method of relieving her recurrent symptoms, which was proven to be effective with less morbidity in long term basis. In conclusion botulinum injection to the puborectalis can be effectively administered under perineal ultrasound scan guidance. Modality of treatment should be decided based on each case to have best outcome and minimize post procedure complications.

## References

1. Wexner SD, Bartolo DC (eds) (1995) Constipation: etiology, evaluation and management. Butterworth-Heinemann, Oxford, pp 1–272
2. Kamm MA, Hawely PR, Lennard-Jones JE (1988) Lateral

- division of puborectalis muscle in the management of severe constipation. *Br J Surg* 75:661–663
3. Farid M, Youssef T, Mahdy T, Omar W, Ayman M, Abdul H, El Nakeeb A, Youssef M. Comparative study between botulinum toxin injection and partial division of puborectalis for treating anismus. *Int J Colorectal Dis* 2009 Mar;24(3):327-34.
4. Madaliński MH, Sławek J, Dużyński W, Zbytek B, Jagiełło K, Adrich Z, Kryszewski A. Side effects of botulinum toxin injection for benign anal disorders. *Eur J Gastroenterol Hepatol* 2002 Aug;14(8):853-6.
5. Gadel-Hak N, El-Hemaly M, Hamdy E, El-Raouf AA, Atef E, Salah T, El-Hanafy E, Sultan A, Haleem M, Hamed H. Pelvic floor dyssynergia: efficacy of biofeedback training. *Arab J Gastroenterol* 2011 Mar;12(1):15-9.
6. Farid M, El Monem HA, Omar W, El Nakeeb A, Fikry A, Youssef T, Yusef M, Ghazy H, Fouda E, El Metwally T, Khafagy W, Ahmed S, El Awady S, Morshed M, El Lithy R. Comparative study between biofeedback retraining and botulinum neurotoxin in the treatment of anismus patients. *Int J Colorectal Dis* 2009 Jan;24(1):115-20.
7. Faried M, El Nakeeb A, Youssef M, Omar W, El Monem HA. Comparative study between surgical and non-surgical treatment of anismus in patients with symptoms of obstructed defecation: a prospective randomized study. *J Gastrointest Surg* 2010 Aug;14(8):1235-43.
8. C S Reiner, MD, R Tutuian, MD, A E Solopova, MD, D Pohl, MD, B Marincek, MD, and D Weishaupt, MD. MR defecography in patients with dyssynergic defecation: spectrum of imaging findings and diagnostic value. *Br J Radiol* Feb 2011; 84(998): 136–144.
9. Ron Y, Avni Y, Lukovetski A, Wardi J, Geva D, Birkenfeld S, Halpern Z. Botulinum toxin type-A in therapy of patients with anismus. *Dis Colon Rectum* 2001;44:1821-1826.
10. Andromanacos N, Skandalakis P, Troupis T, Filippou D. Constipation of anorectal outlet obstruction: pathophysiology, evaluation and management. *J Gastroenterol Hepatol* 2006;21(4):638–646.
11. Maria G, Brisinda G, Bentivoglio AR, Cassetta E, Albanese A. Botulinum toxin in the treatment of outlet obstruction constipation caused by puborectalis syndrome. *Dis Colon Rectum* 2000;43:376-380.
12. Yong Zhang, Zhen-Ning Wang, Lei He, Ge Gao, Qing Zhai, Zhi-Tao Yin, Xian-Dong Zeng. Botulinum toxin type-A injection to treat patients with intractable anismus unresponsive to simple biofeedback training. *World J Gastroenterol* 2014 September 21; 20(35): 12602-12607