

## Laparoscopic spleen preserving distal pancreatectomy

A. B. U. Indrajith<sup>1</sup>, AD Darmapala<sup>1</sup>, W. G. P. Kanchana<sup>1</sup>, D. D. Karunasagara<sup>1</sup>, T. Jayasingharachchi<sup>2</sup>, V. Pinto<sup>2</sup>, K. B. Galketiya<sup>1</sup>

<sup>1</sup>Department of Surgery, Teaching Hospital Peradeniya, Sri Lanka

<sup>2</sup>Department of Anaesthesiology, Teaching Hospital Peradeniya, Sri Lanka

**Keywords:** Laparoscopy; distal pancreatectomy; spleen preserving

### Introduction

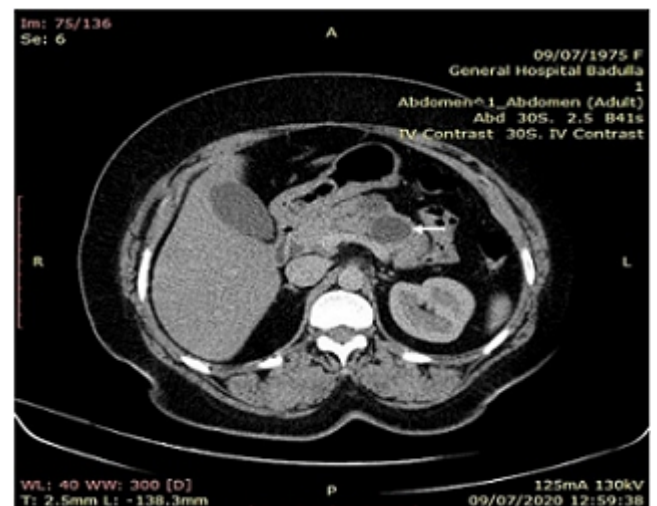
Minimally laparoscopic distal pancreatectomy is the curative treatment for tumours of the pancreatic body and tail. When performed by laparoscopy the morbidity is reduced [1]. The procedure may be with or without splenectomy. Spleen preservation needs preserving the splenic artery and vein. The alternative is to provide splenic perfusion via short gastric vessels [2]. We present a case of a patient who underwent laparoscopic spleen preserving distal pancreatectomy for a mucinous cystic neoplasm of the pancreatic body. The standard way of dividing the pancreas is by a stapler. If divided by another form the open end is sutured. We have deviated from this by dividing the pancreas by coagulating with bipolar diathermy and transacting with an ultrasonic dissector and leaving the stump unsutured. This is our standard practice for many years.

### Case presentation

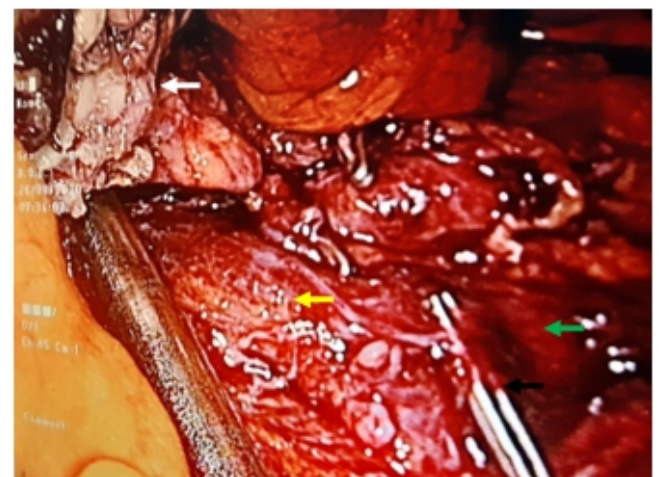A 45-year female patient, who had presented with vague upper abdominal pain had a cystic mass of the pancreatic body on ultrasound scan. CECT abdomen revealed mucinous cystic neoplasm measuring 66 mm [Lat] 44mm[AP] 53mm [CC] in size [Figure 1].

After obtaining informed consent a laparoscopic spleen preserving distal pancreatectomy was performed. The patient was positioned in the right lateral position with head-end elevated. Five ports were used including the camera port. The gastrosplenic ligament was divided. Then transverse colon and splenic flexure were reflected down. The pancreas was dissected off the posterior abdomen exposing the splenic vein. The splenic artery was dissected at the superior border of the pancreas. The splenic artery and splenic vein were completely dissected of the pancreas. The splenic vein was cleared up to the confluence with the superior mesenteric vein forming the portal vein [Figure 2].

The pancreas was divided at the neck using bipolar diathermy and ultrasonic dissector. The divided body and tail was gently freed off and removed using a retrieval bag. The operative time was 210 minutes with a blood loss of less than 100ml. The specimen was removed by minimally enlarging a port site [Figure 3].



**Figure 1.** White arrow showing the pancreatic cystic neoplasm



**Figure 2.**

White arrow - Cut edge of the pancreas

Yellow arrow - Portal vein

Green arrow - Splenic vein

Black arrow - clipped off branch of the portal vein

Correspondence: W. G. P. Kanchana

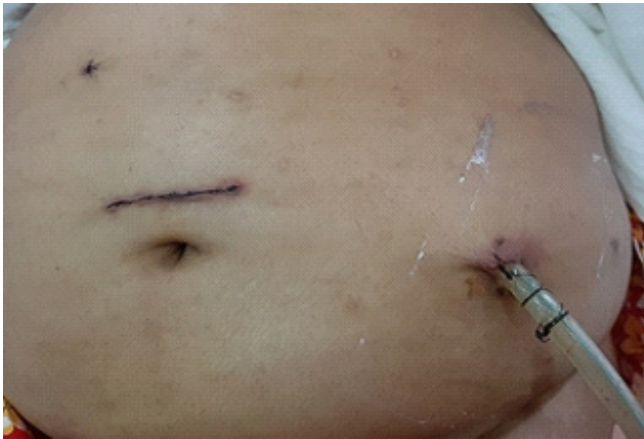E-mail: pulasthi@live.com

<https://orcid.org/0000-0002-0482-3341>

Received: 22-11-2020 Accepted: 03-07-2021

DOI: <http://doi.org/10.4038/sljs.v39i3.8768>





**Figure 3.** Port sites and incision for specimen retrieval.

Postoperatively patient received ICU care for one day and was discharged from the ward on postoperative day 6. She had an eventful recovery. The drain amylase was 5020 IU/L on day one which was reduced to 200 IU /L by day three. The histopathology revealed a mucinous cystic neoplasm of the pancreatic body with clear resection margins.

### Discussion

Distal pancreatectomy when performed by minimal access is associated with reduced morbidity [3]. The patient presented had a speedy recovery and did not require narcotic analgesics from day one. If the splenic hilum is involved en block splenectomy is required. However, when CECT was analyzed in our patient, it was decided to preserve the spleen which prevents post-splenectomy related problems. However, spleen preserving surgery is more technically demanding. There are two techniques to preserve the spleen with distal pancreatectomy. Either by preserving both the splenic artery and vein [2] or by blood supply from short gastric vessels with splenic artery and vein being divided [3,4].

In our case of distal pancreatectomy, the splenic artery and vein were preserved to perfuse the spleen. The surgery was completed at an acceptable time and with minimum blood loss. There are many ways to divide the pancreas. It is often done using a stapler. Another alternative is to divide and suture the stump [5]. In our unit, over many years we use bipolar diathermy and ultra-sonic dissector and there had been no complications due to pancreatic fistula.

### Conclusions

In the patient presented laparoscopic spleen preserving distal pancreatectomy with preserving splenic artery and vein was performed in an acceptable time with minimal blood loss. The standard practice of our unit, dividing the pancreas with bipolar diathermy and ultrasonic dissector and leaving the stump open was well tolerated.

All authors disclose no conflict of interest. The study was conducted in accordance with the ethical standards of the relevant institutional or national ethics committee and the Helsinki Declaration of 1975, as revised in 2000.

### References

1. Bashir MU, Kandilis A, Jackson NM, Parikh JA, Jacobs MJ. Distal pancreatectomy outcomes: Perspectives from a community-based teaching institution. *Ann Hepato-Biliary-Pancreat Surg.* 2020 May 31;24[2]:156–61. <https://dx.doi.org/10.14701%2Fahbps.2020.24.2.156>
2. Kimura W, Yano M, Sugawara S, Okazaki S, Sato T, Moriya T, et al. Spleen-preserving distal pancreatectomy with conservation of the splenic artery and vein: techniques and its significance. *J Hepato-Biliary-Pancreat Sci.* 2010 Nov;17[6]:813–23. <https://doi.org/10.1007/s00534-009-0250-z>
3. de Rooij T, Sitarz R, Busch OR, Besselink MG, Abu Hilal M. Technical Aspects of Laparoscopic Distal Pancreatectomy for Benign and Malignant Disease: Review of the Literature. Vol. 2015, *Gastroenterology Research and Practice.* p. e472906. <https://doi.org/10.1155/2015/472906>
4. Wang L, Wu D, Cheng Y, Xu J, Chu H, Zhang G, et al. Warsaw Technique in Laparoscopic Spleen-Preserving Distal Pancreatectomy: Surgical Strategy and Late Outcomes of Splenic Preservation. *BioMed Res Int.* 2019:1–10. <https://doi.org/10.1155/2019/4074369>
5. Tiefertunk E, Demir IE, Schorn S, Sargut M, Scheufele F, Calavrezos L, et al. Pancreatic stump closure techniques and pancreatic fistula formation after distal pancreatectomy: Meta-analysis and single-center experience. *PLoS ONE.* 2018 Jun ;13[6]. <https://dx.doi.org/10.1371%2Fjournal.pone.0197553>.

### Learning Points:

- Dissecting and preserving splenic artery and vein are key points in spleen preserving distal pancreatectomy.
- As both of these vessels are retroperitoneal laparoscopic visualization is better than open approach due to angle of vision and magnification.
- With better vision, pneumoperitoneum too helps to dissect vessels. Once areolar tissues around vessels are opened gas gets in to dissecting plane facilitating vascular control.